

CAD/CAM abutment design with constant emergence profile and single insertion

Optimized emergence profile

DR CARLOS GARGALLO GÁLLEGO*, BARCELONA, SPAIN

CAD/CAM-designed and manufactured implant-supported dental prostheses have thoroughly transformed our daily practice. CAD/CAM restorations as a standard treatment modality improve treatment quality. Virtual design and the digital workflow give us control over the manufacturing process.

Introduction

The “One abutment – one time” concept aims to prevent the hemidesmosomal rupture caused by frequent denture insertion and removal, thus improving the stability of the soft tissue around implants. Three-dimensional implant positions are planned subject to specific insertion protocols (subcrestal, paracrestal, tissue-level type). Special laser treatments improve the apposition of soft tissue to the implants, seeking to provide a seal against bacterial infiltration. Implant treatments thus depend on multiple variables that will determine our selection of treatment modalities and materials.

The objective of this article is to present a clinical protocol with indexed conical-connection implants, ideally placed 2 mm subcrestally, with CAD/CAM restorations that match the critical subcrestal profile and therefore require a precise emergence profile, while minimizing the number of denture retrievals during the process.

Case reports

An accurate and specific preimplantological diagnosis requires several parameters to be examined: the patient’s needs, the condition of the soft and hard tissues, an accurate 3D analysis of the case, the choice of the implant system, and the modalities of implant placement and subsequent CAD/CAM restoration. Other parameters will also have a direct impact on the treatment, such as the surgeon’s skill and experience and the patient’s oral hygiene, motivation, economic resources and expectations.

The following two case reports describe the treatment protocol from diagnosis to conclusion, with step-by-step descriptions of the CAD/CAM subcrestal restoration treatment procedure adopted, and including evolution two years after treatment.

Case 1

Medical history

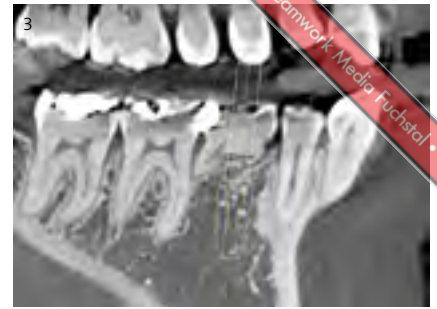
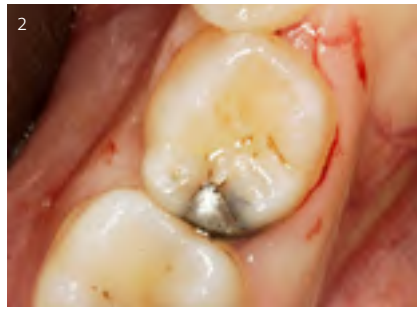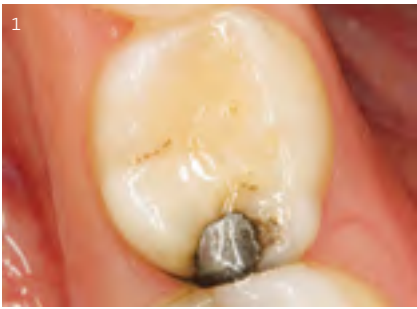38 years old patient; no contributory history; mobility in the persisting deciduous teeth 85 and 75 (with agenesis of teeth 45 and 35); normal periodontal status and good oral hygiene (Figs. 1 and 2).

Treatment plan

A 3D design system (Dentsply Sirona, Germany) was used to plan the extraction of teeth 85 and 75 with immediate placement of implants (Axiom PX, 4 × 12 mm; Anthogyr, France) (Fig. 3). This implant features a 6-degree conical connection with trilobate apical indexing to stabilize the element if appropriate, a completely etched surface, subcrestal placement of at least 1 mm – making the implant subosseous – and platform switching integrated with a reverse conical neck module. It has a spiral design indicated especially for immediate post-extraction placement in porous bone.

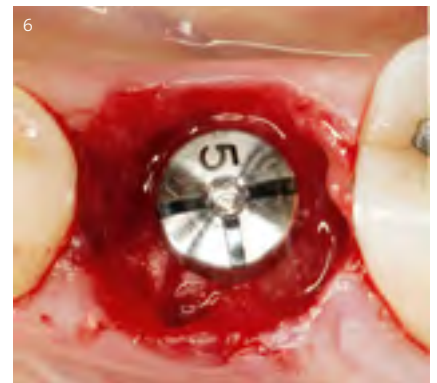
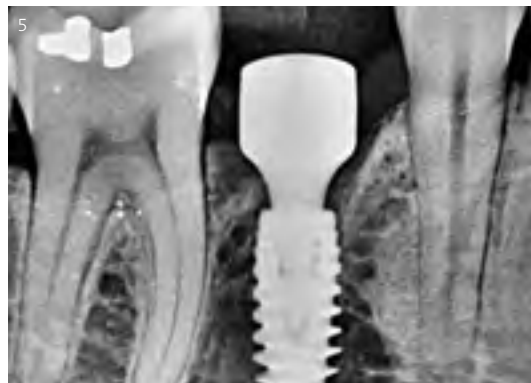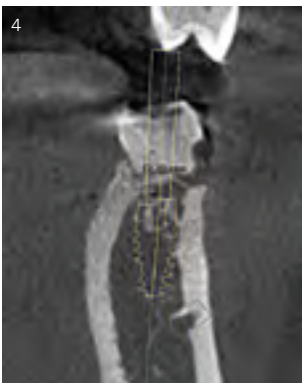Implants were to be placed 2 mm subcrestally to promote the growth of bone tissue on the implant and to avoid the critical area of the paracrestal connection, counteracting the bacterial proliferation often present when using implant systems with no conical connection and no paracrestal placement.

* Odontologist, Universitat Internacional de Catalunya; Dental prosthetist, Escola Francesc Pejoan; Postgraduate in Advanced Cosmetic Dentistry, Academia Ciències mèdiques; International Master in Oral Implantology and Hard and Soft Tissues; private practice in Barcelona, Spain



1 and 2 | Mobility in the persisting deciduous teeth 85 and 75 (with agenesis of teeth 45 and 35).

3 | Planning of implant placement.



4 | Planning of implant placement.

5 | X-ray after implant placement.

6 | Occlusal view of the healing screw after implant placement.

Additionally, this type of placement improves the emergence profile of the restored tooth and makes it more gradual (Fig. 3).

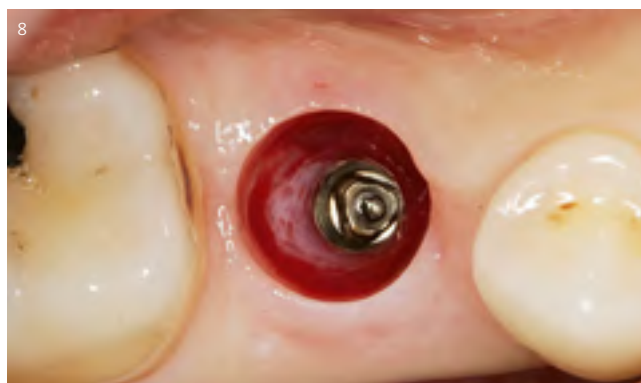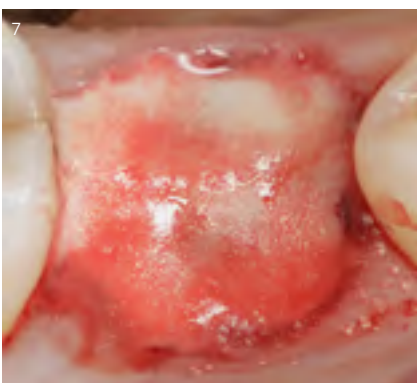The day before the surgery, an impression was taken for the fabrication of a custom perforated tray designed for taking an impression of the implant position on the day of surgery, so as to avoid having to remove elements on subsequent visits. (This step may be postponed until after osseointegration, especially if gingival stability might be an issue.)

After extracting tooth 85, the implant was inserted at a torque 40 Ncm. It was decided not to fill the alveolar space. A healing abutment 4.5 mm in height and 6 mm in diameter was placed. The procedure was repeated for tooth 75, with an Axiom PX

implant (4 × 12 mm) inserted at a torque of 40 Ncm. The healing abutment was 3.5 mm long and 5 mm in diameter. For this tooth, the defect volume was filled with Putty (OsteoBioL; Tecnos, Italy) just past the soft tissue (Figs. 4 to 6).

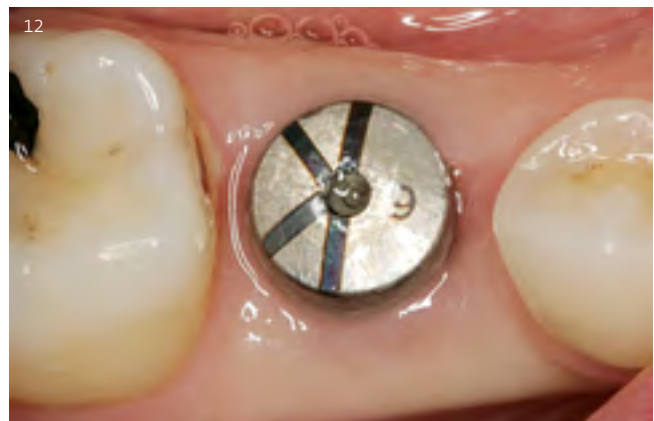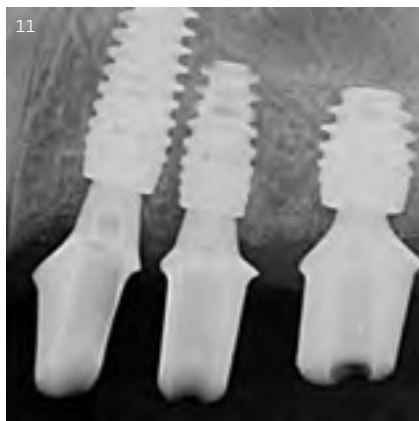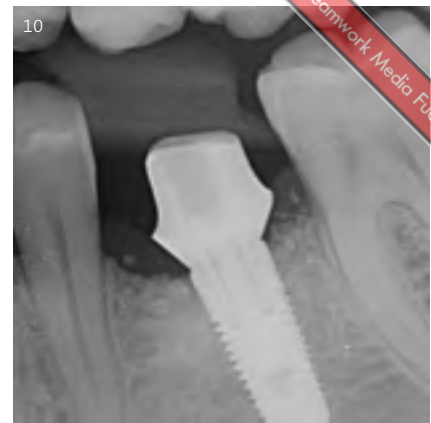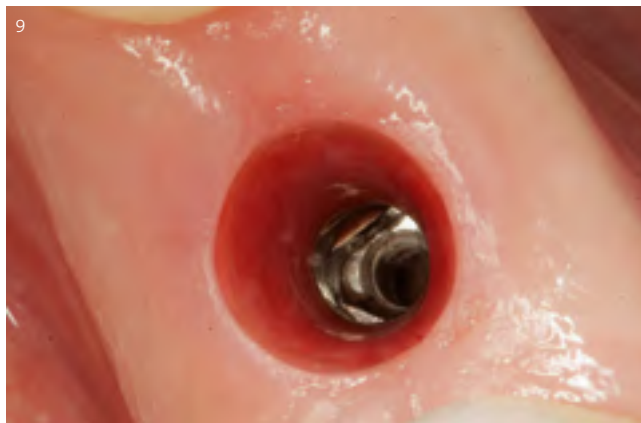After a three-month osseointegration period, an impression was taken with a hard, polyether-type material (Impregum Penta; 3M, Germany). The maturation of the soft tissue was exceptional, as the biological space necessary for proper soft tissue maturation had been respected (Figs. 7 and 8).

We splinted both sides of the transfer with small amounts of photopolymerizable Triad gel. This gel must be stored refrigerated and should be removed from the refrigerator only shortly before use because it loses its viscosity rapidly at room temperature.



7 and 8 | After the three-month osseointegration period, the maturation of the soft tissue was exceptional, as the necessary biological space had been respected.

- 9 | Gingival healing.
- 10 | Paracrestal implant; the abutment has no subcrestal part.
- 11 | X-ray of a case illustrating the emergence profile of Simedra customized abutments.
- 12 | Interproximal spaces.



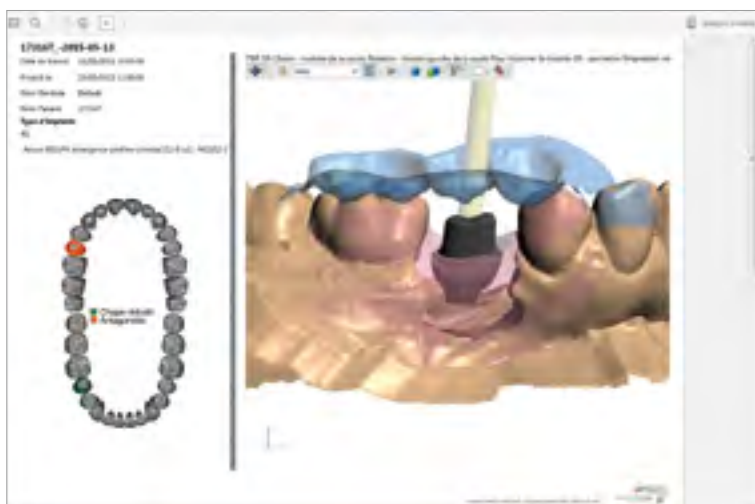
CAD/CAM subcrestal abutment design, step 1

In the traditional technique, the working model is made with abundant soft pink silicone around the transfer coping and the implant analogue to make it easier to remove and read it with a scanner, preventing scanning artefacts and errors. This method is recommended if the implant is placed in a paracrestal position, as the CAD/CAM abutment will trace a gingival trajectory and compress the surrounding soft tissue, according to its design (Fig. 9).

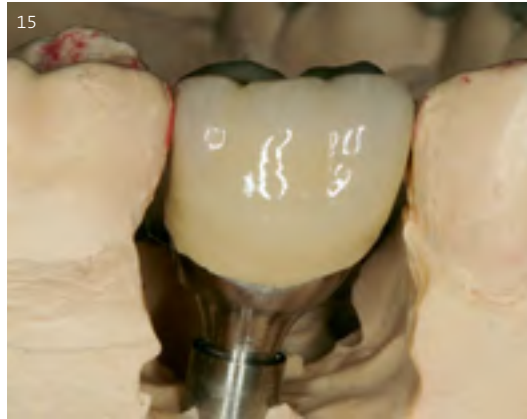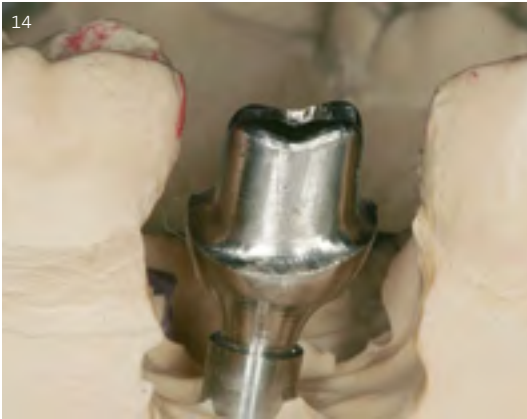However, if the implant is placed 2 mm subcrestally, a portion of the pink silicone cast will actually correspond to the hard tissue above the implant and only part of the pink silicone will correspond to the actual soft tissue.

Normally, the bone tissue must be left uncompressed, so the abutment will have to adapt perfectly to the bone area in order to compress the soft tissues in the coronal section. As a result, most of the subcritical profile of the abutment is located "in the bone" and only the ridge (the critical profile of the abutment) and one-third of the coronal section is located in the soft tissue (Fig. 10).

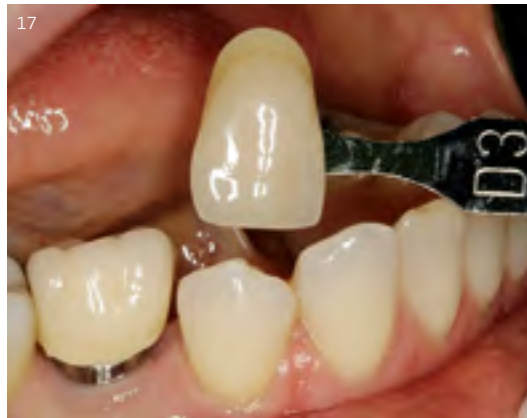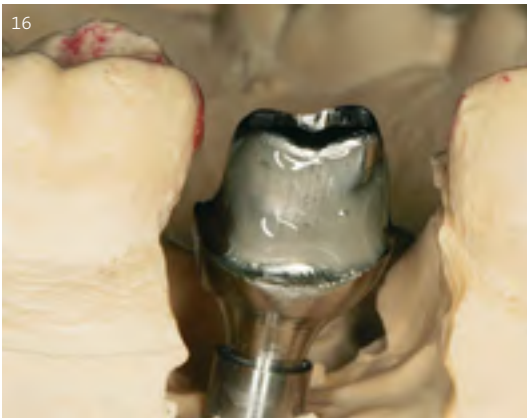To correctly identify the emergence profile and reproduce it without compromising the proper placement of the abutment within the subcrestal section, the definitive abutment was designed based on the healing abutment. The Anthogyr implant range offers what is called "constant emergence profile between elements": All standard and healing abutments, Locator abutments, etc. match the healing abutments used. All that was needed was to provide the manufacturing centre with the details of the healing abutment representing the correct gingival height. The Anthogyr Simedra production centre used this information to design a titanium abutment with the same emergence



13 | Abutment design by Simedra.



14 and 15 |
Abutment and
crown are checked
on the model.



16 |
The crown/abut-
ment assembly
was cemented
extraorally with a
dual-curing resin
cement.

17 |
Insertion of the
abutment.

profile, ensuring accurate placement of the CAD/CAM-designed model with no bone interference.

Past the two-thirds of the constantly emerging apical section, the abutment in the coronal third can be designed to give as much support as possible to the soft tissue and the tooth, ideally screwed and sealed for extraoral cementation.

The abutment was designed with ExoCad and verified with a simple interactive PDF. Ideally, the contact points of the abutment are a projection of the distal and mesial margins. The emergence profile goes from being concave in its apical two-thirds to promote bone apposition, to being convex on its coronal third to extend the projection to the points of contact and the sides. The objective is to provide maximum possible support to the soft tissue and crown, to close open spaces and to prevent, as far as possible, the accumulation of food in the interproximal space (Figs. 11 and 12).

The next step after the abutment design had been approved was the choice of material. A milled titanium abutment is recommended for a good implant/abutment interface made of the same material. This is another reason why the prosthesis would optimally be screwed and cemented to let the operator choose the material of the crown without compromising the interface.

CAD/CAM subcrestal abutment design, step 2

The Anthogyr Simeda production centre designed the abutment (Fig. 13) and returned it with a new screw. Before it was sent to the laboratory for production of the crown, the screw was replaced with the one provided by the distributor, shipped together with a copy (analogue) of the implant. This is a significant advantage as it guarantees that the screw is "virgin" and used for one insertion only and tightened only once.

The crown manufactured by the production centre was checked on the model sent with the abutment and intraorally without the abutment. The intraoral check also verifies the correct shade and shape, which is possible in this system without removing the healing abutment placed on the day of surgery. The crown fit rather well in the mouth, since its base was hollow because the milled abutment had not yet been placed (Figs. 14 and 15).

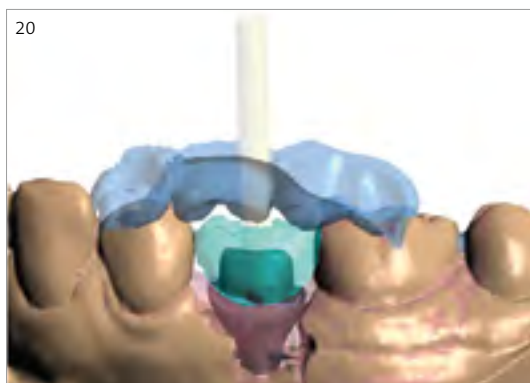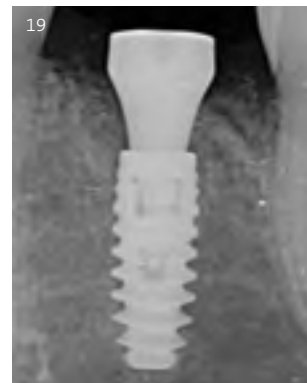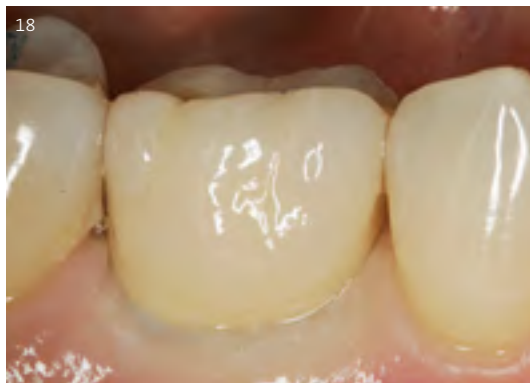When the abutment was considered ready to be placed in the mouth, the crown/abutment assembly was cemented extraorally with a dual-curing resin cement (Fig. 16). After extraoral polishing and checking, the abutment was inserted in the mouth through the crown opening as if it were a crown to be screwed directly on the implant (Fig. 17). The insertion torque was 25 Ncm. The abutment was

introduced with hardly any discomfort for the patient and without interfering with the bone.

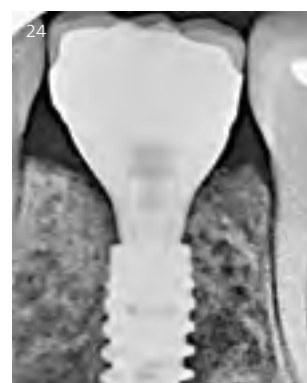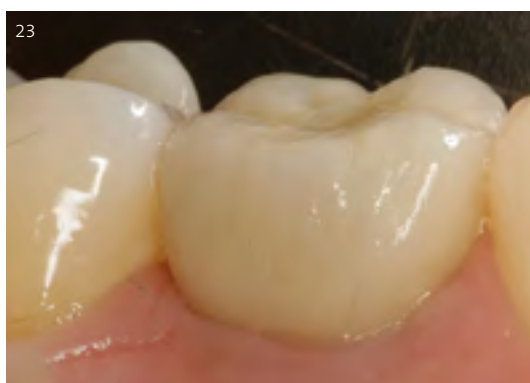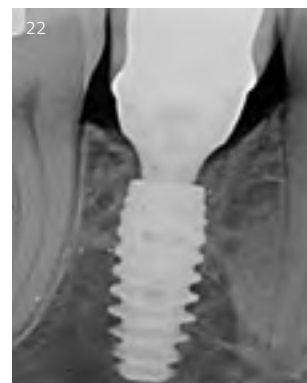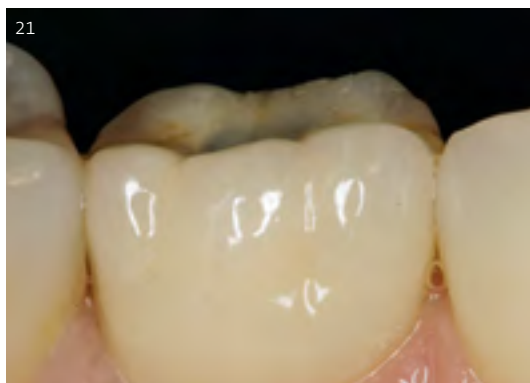The same process was repeated at the site of the previous tooth 75, but adding a double-scanning technique to the 3D design to improve the spatial

design of the abutment (Figs. 18 to 20). The tooth was placed in the mouth in the same way as on the other side, with screwing and sealing at a torque of 25 Ncm. Figures 21 to 24 show the situation two years after implant placement.

18 to 20 |
The process is repeated on tooth 75 with an additional double-scanning technique to the 3D design to improve the spatial design of the abutment.



21 to 24 |
The situation of Case 1 two years after implant placement.



Case 2

Medical history

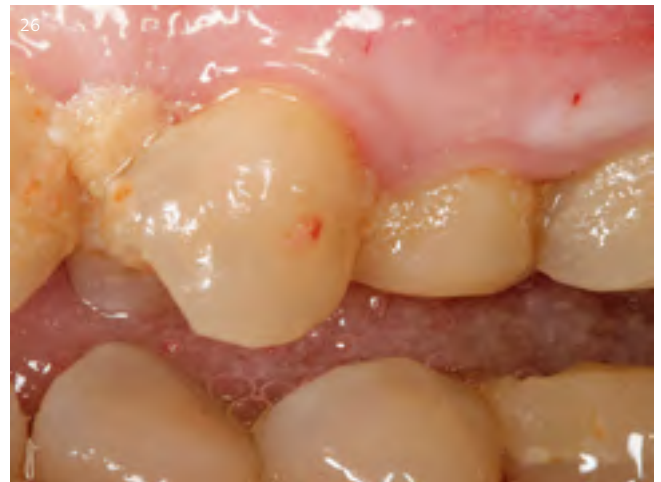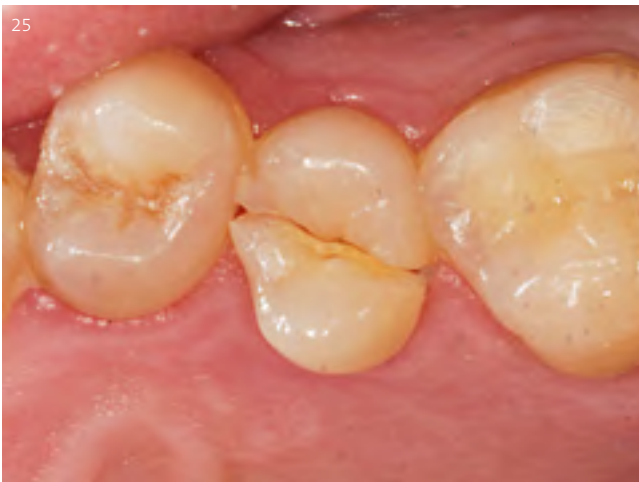48 years old patient; no contributory history; thick periodontal tissue and poor oral hygiene. The patient presented with acute pain in tooth 15. The clinical examination showed a vertical fracture of this tooth and generally poor oral hygiene (Figs. 25 and 26).

Treatment plan

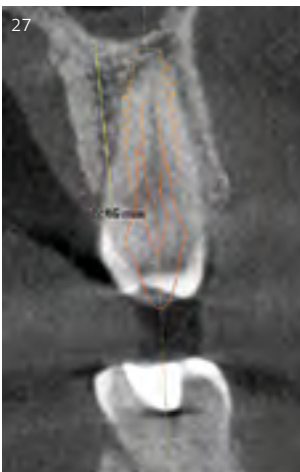
An emergency periodontal treatment was performed and tooth 15 was extracted. An implant was planned using a 3D CT scan (Dentsply Sirona, Germany). The patient refused gingival modelling after surgery. An Axiom PX implant (4 x 12 mm; Anthogyr, France) was placed in a flapless technique (Fig. 27) in an attempt to keep the soft tissue as stable as possible. The gap was filled with Putty (OsteoBiol, Italy) and the healing abutment placed to define the initial emergence profile (Fig. 28).

The healing abutment was 4.5 mm long. This abutment length is among the most frequently used for markedly subcrestal placements. At this point, there are three options without immediate loading:

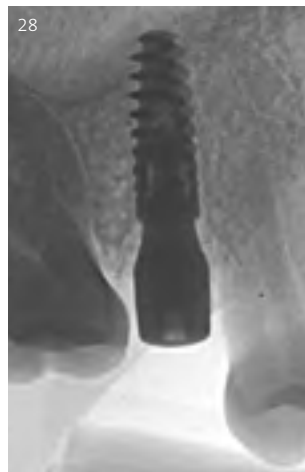1. Keeping the healing abutment in place as inserted.
2. Modifying the healing abutment at the level of the paragingival margin to give it more volume and create a more customized emergence profile, according to the tooth to restore. This modification can be made with composite or other materials (Fig. 29).
3. Using the initial digital workflow when designing and manufacturing a healing abutment placed on the day of the surgery, normally from titanium and PMMA, for later transfer of this digital design to the permanent element (DAP technique, *Dr Carlos Repullo*).



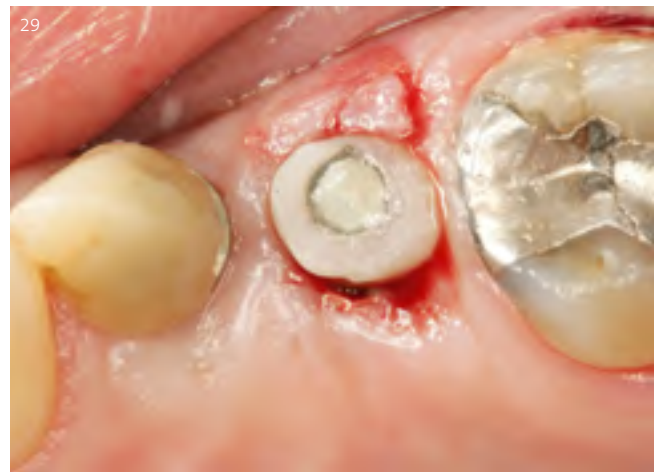25 and 26 | The clinical examination showed a vertical fracture of tooth 15 and generally poor oral hygiene.



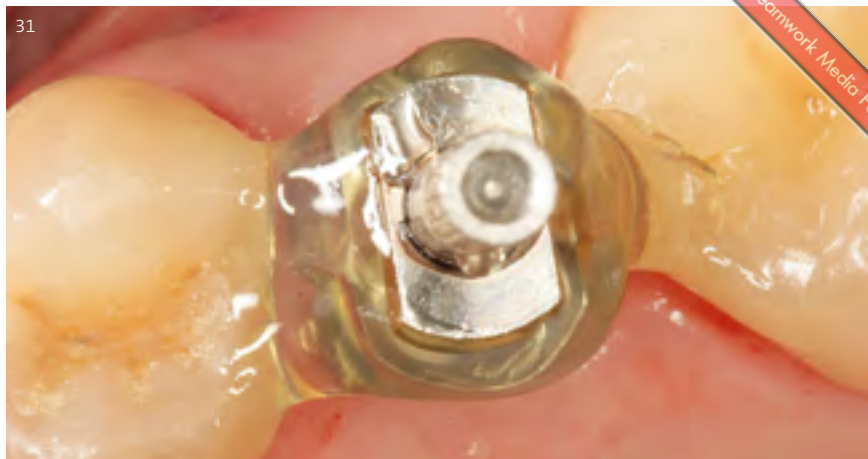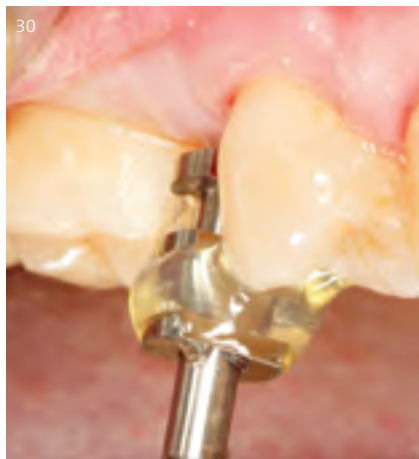27 | After careful extraction of tooth 15, an Axiom PX implant (4 x 12 mm; Anthogyr, France) is inserted.



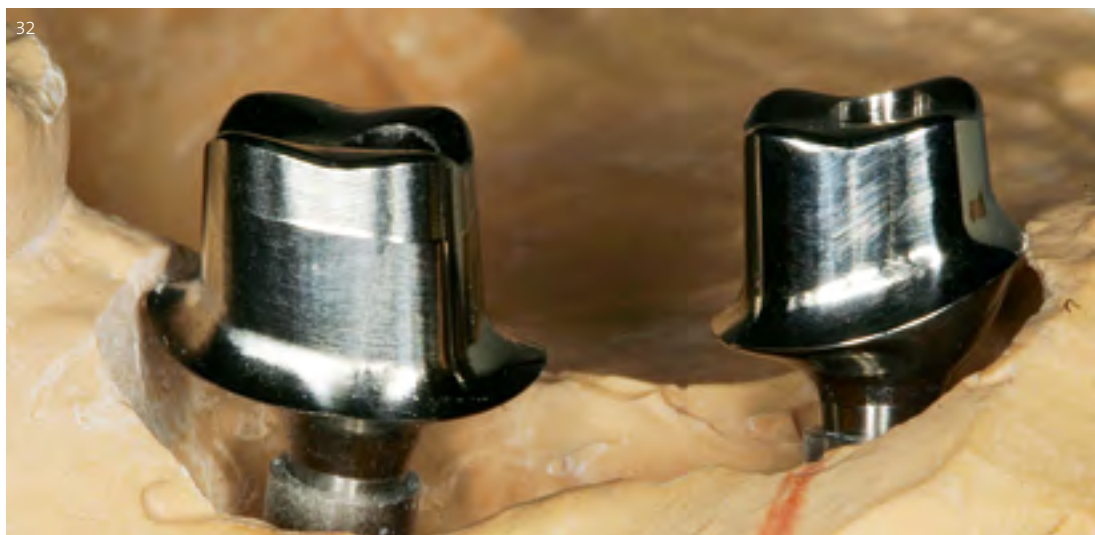28 | The healing abutment is placed to define the initial emergence profile.



29 | Modification of the healing abutment at the level of the paragingival margin to give it more volume and create a more customized emergence profile.



30 and 31 | Application of Triad gel. The polyether paste should be introduced from below to avoid dislodging the Triad gel in the embrasures.



32 | Situation where the future abutment cannot be placed on the model accurately due to its width and because it interferes with the mesial and distal plaster.

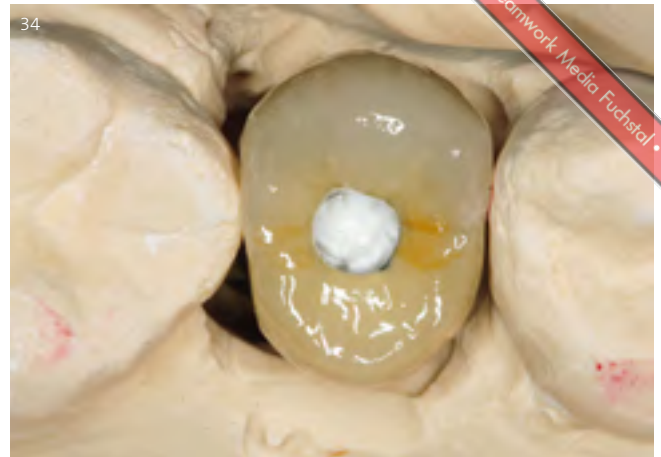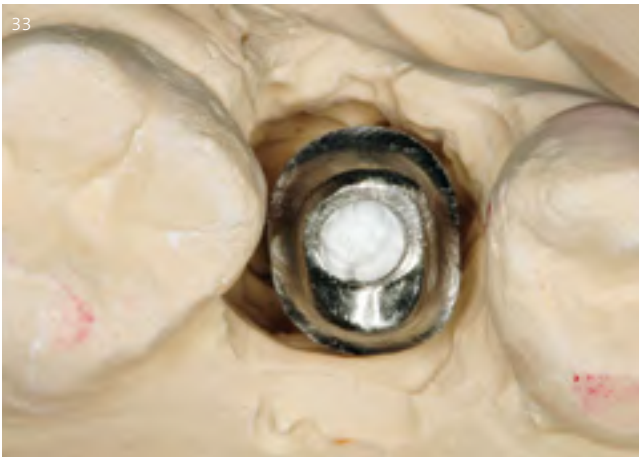After a three-month osseointegration period, an impression was taken. At this stage, it is particularly useful to have a system that preserves identical emergence profiles between elements, as gingival resorption – which may occur during site preparation and consolidation with the transfer of the impression – is minimized, and the patient does not feel discomfort due to the change and introduction of different elements, as had been the case if option 1 had been adopted for the healing abutment.

The Triad gel applied had to be extended as far as the contact points of the contiguous elements to obtain a double anti-rotational lock of the transfer element for the open-tray impression, when the analogue was to be screwed into the impression. Thus, the transfer element remained locked by the indexed connection of the implant and by the other elements. It is not necessary for the Triad gel to support the entire arch of the impression all the

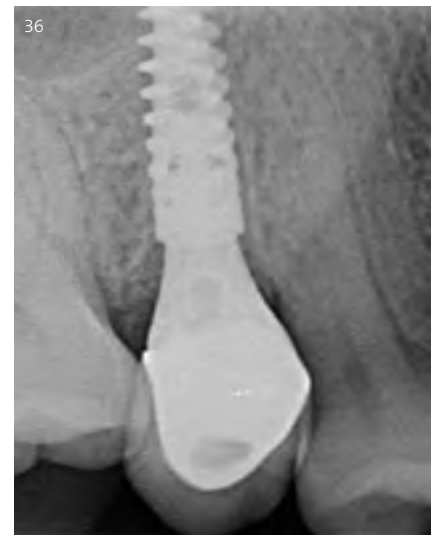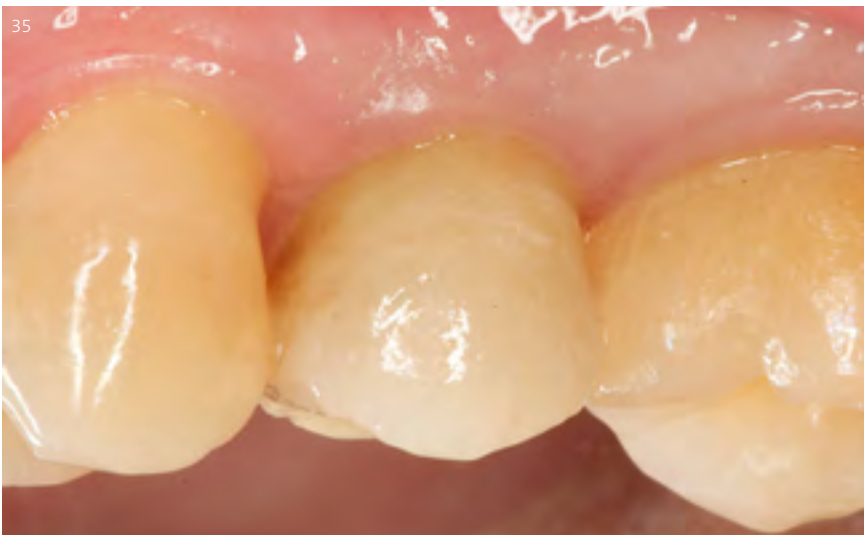way to the gingival section; however, the polyether paste should preferably be introduced from below to avoid dislodging the Triad gel in the embrasures in case of incorrect insertion axes (Figs. 30 and 31).

Pink silicone (Gi-Mask; Heraeus Kulzer, Germany) was placed and extended beyond the analogue/implant connection all the way to the apical section, for the same reason as in the previous case. Had a wide and compressive profile been considered, it would have been advisable to mould the mesial and distal ends of the impression in pink silicone to prevent a situation where the future abutment cannot be placed on the model accurately due to its width and because it interferes with the mesial and distal plaster (Fig. 32).

The next step was the virtual design of the abutment. The emergence profile of the healing abutment (4 mm in diameter and 4.5 mm in length) was again applied. If the position of the implant makes



33 and 34 | Final abutment and final crown on the model.



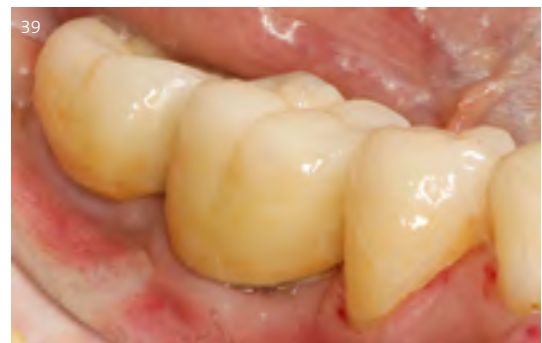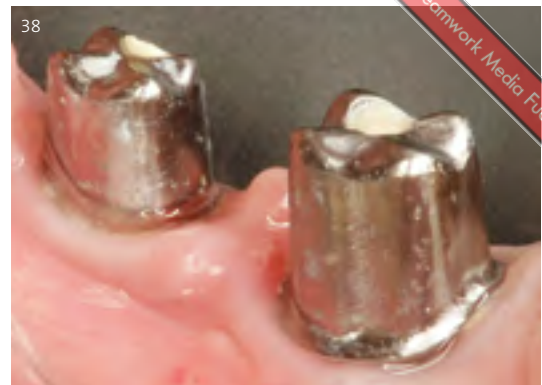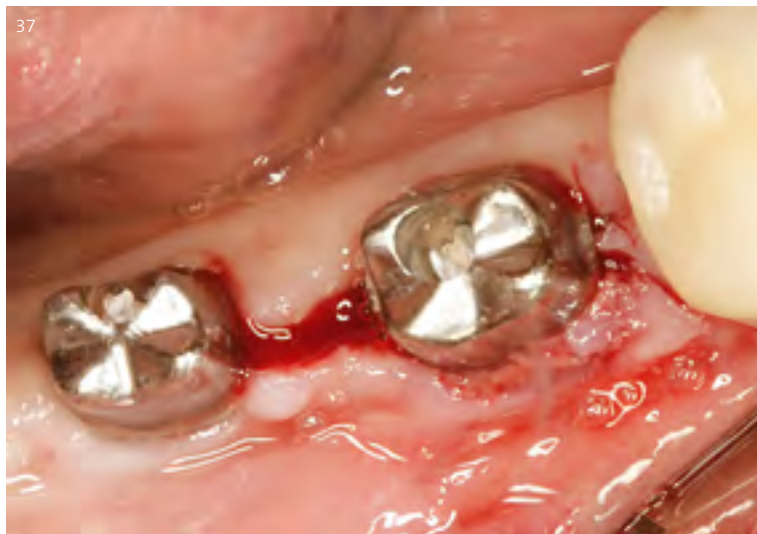35 and 36 | The situation of Case 2 two years after implant placement.

an aesthetically viable screwed and sealed prosthesis impossible, and calls for a cemented restoration, placing the distal and lingual margins of the CAD/CAM abutment in a slightly supragingival position is recommended to minimize possible issues associated with oral cementation. In areas without aesthetic concern, there is no reason to hide margins subgingivally.

Once the abutment and crown had been delivered and the necessary checks performed, the laboratory screw was replaced with the permanent screw. The sealing should preferably be performed extraorally with the screw already inserted, as this will allow the diameter of the crown ridge to be smaller if desired, and the screw will act as a “retaining screw”. This technique provides better aesthetic results and requires less additional sealing with permanent material, with a lower risk of accidentally losing the screw. The wrench should enter easily through the

crown without touching the walls to enable more precise torque control and to avoid building stress in the crown when tightening, which may cause decementation of the abutment (Figs. 33 and 34). The element was placed and tightened at 25 Ncm with no anaesthesia. Figures 35 and 36 show the situation two years after placement.

A large critical profile with extensive compression of the soft tissue can impair the penetration of the crown/abutment element, making its insertion difficult. In this case, the thickness in the central line of soft tissue should be partially reduced to open it and to allow the insertion of the prosthesis. The present procedure, however, will increase the amount of vestibular soft tissue of the prosthesis and improve the emergence profile. Suturing the soft tissue with 6-0 absorbable suture is recommended to minimize tissue damage and to keep the tissue in the desired position to prevent its collapse (Figs. 37 to 39). >>



37 to 39 | Illustrations of a case in which the soft tissue thickness was reduced in order to allow the insertion of the prosthesis.

Conclusions

Several techniques and working protocols are available today to treat our patients successfully – but all of them are based on an accurate diagnosis and treatment plan, anticipating any complications. Some of these complications are inevitable and need to be resolved as they appear, but the working protocol adopted in the two cases described here allowed us to control and direct the treatment course in the best possible way. The success or failure of a treatment is not determined by a single factor but by a combination of factors, some more and some less significant.

Hemidesmosomal ruptures caused when inserting or removing prosthetic elements on various occasions can result in suboptimal tissue adhesion to the implant while unintentionally promoting bacterial contamination of the peri-implant area, even if this is not evident initially. Placing the connection of the prosthesis away from this area and using a long conical connection sealed as tightly as possible helps avoid these issues. If the implant is placed subcrestally, this also improves the emergence profile of the CAD/CAM abutment and closes the embrasure spaces more efficiently, as the sub-critical profile of the abutment is more progressive. This is why it is very important to insert the CAD/CAM abutment only once if at all possible, and to start creating the contour of the emergence profile on the same day as the surgical procedure and keep it stable at both the bone and gingival level.

The CAD/CAM abutment design with the same emergence profile greatly facilitates standard clinical treatment and results in higher patient satisfaction, without requiring sophisticated techniques to register the emergence profile.

It is not as if the emergence profile transfer technique was not valuable or adequate. But the technique of copying the profile in the CAD/CAM abutment provides good results that make the transfer technique redundant while reducing the number of appointments and the number of times the prosthetic elements are retrieved from the mouth.

In cases where the critical profile should be improved and there are doubts about the soft-tissue support, we will always have to see if it is possible, as advised here, to place the permanent CAD/CAM abutment and associate a provisional one. If we do not wish to remove the CAD/CAM abutment, we will only have two options: either make a copy of the abutment and proceed to retrieve the supra-structure – with or without a crown profile transfer – or apply a digital protocol that allows scanning the abutment directly for the digital production of the crown without a model. ■

The references are available at www.teamwork-media.de/literatur

Contact address

Clinica Dental Dr Carlos Gargallo
Carrer de l'Escorial, 8
08024 Barcelona · Spain
cgargallo@yahoo.com